

Unilateral hyperkeratotic dark plaques covering the entire right lower extremity: A rare entity

Ecem Bostan¹

ORCID: 0000-0002-8296-4836

Basak Yalici-Armagan²

ORCID: 0000-0001-9745-1331

Beril Yel²

ORCID: 0000-0002-8863-1311

Ozay Gokoz³

ORCID: 0000-0001-9537-1127

¹Cihanbeyli State Hospital, Dermatology and Venereology Clinic, Konya, Türkiye.

²Department of Dermatology and Venereology, Hacettepe University, Faculty of Medicine, Ankara, Türkiye.

³Department of Pathology, Hacettepe University, Faculty of Medicine, Ankara, Türkiye.

Corresponding Author: Ecem Bostan
E-mail: bostanecem@gmail.com

Received: 15 June 2022, Accepted: 20 December 2022,
Published online: 27 December 2022

ABSTRACT

Verrucous venocapillary malformation, formerly known as verrucous hemangioma, presents itself as single or multiple, well-demarcated, erythematous plaques that eventually acquire hyperkeratinization, oozing, bleeding and become thicker and darker over time. We report a case of verrucous venocapillary malformation in 33-year old woman referred to the dermatology outpatient clinic with the complaint of hyperkeratotic plaques covering the entire right leg and thigh, present since birth.

Keywords: diagnosis, differential, pathology, vascular malformations.

INTRODUCTION

Verrucous venocapillary malformation (VVM), formerly known as verrucous hemangioma, is characterized by well-demarcated, single or multiple, dark red/purple or black verrucous plaques and nodules which may show hyperkeratinization, thickening, darkening and bleeding [1,2]. VVM usually appears at birth or during early childhood [2]. On the other hand, angiokeratomas are well-demarcated vascular lesions which are characterized histopathologically by superficial vascular ectasia accompanied by hyperkeratosis [3]. Some clinical variants of angiokeratomas include solitary or multiple angiokeratomas, angiokeratoma of the vulva and scrotum, angiokeratoma corporis diffusum (ACD), angiokeratoma circumscriptum nevirforme (ACN) [3]. Apart from the other types of

angiokeratomas, ACN is the only congenital variant of all angiokeratomas [3]. Additionally, ACN is not associated with any inborn errors of metabolism of lysosomal storage, typically Fabry's disease [3]. ACN generally appears at birth or during early childhood and typically manifests itself in the form of hyperkeratotic, violaceous, verrucous plaques just like VVM [4]. Therefore, it is quite essential to differentiate VVM from ACN and histopathological examination is the gold standard for the prompt diagnosis [4]. We report the clinical case of a 33-year old woman referred to the dermatology outpatient clinic with the complaint of dark purple/black hyperkeratotic plaques covering the entire right leg and thigh, present since birth.

CASE PRESENTATION

A 33-year old woman referred to the dermatology outpatient clinic with the complaint of noncompressible, dark purple/black hyperkeratotic plaques covering the entire right leg and thigh. The lesions were present since birth; gradually enlarged and transformed into nontender, verrucous nodules. Magnetic resonance imaging was performed in another institution and revealed the presence of exophytic lesions with deeper subcutaneous and soft tissue involvement on the right extremity, suggestive of VVM. However, no histopathological examination was performed. Our differential diagnoses include verrucous venocapillary malformation, angiokeratoma circumscriptum neviforme (ACN) and glomuvenous malformation. Dermatological examination revealed purpuric-black, discrete/confluent, hyperkeratotic plaques and nodules with variable sizes covering the entire medial right lower limb (Figure 1). There was no mucosal involvement. Histopathological examination showed epidermal hyperkeratosis and elongation of the rete ridges. In the papillary dermis, ectatic small vessels which were surrounded by the elongated rete ridges, were observed (Figure 2A-B). Serial sections revealed malformed

vascular proliferations in the subcutaneous tissue and deep dermis was spared (Figure 3A-B). Vacuolization of endothelial cells or lipid inclusions were not present. Since the subcutaneous tissue involvement was apparent, she was diagnosed with VVM with the help of clinical, radiological and histopathological findings. She was referred to plastic and reconstructive surgery department for the excision and split-thickness skin grafting of the large plaques and nodules.

DISCUSSION

VVM, also known as verrucous hemangioma, is a rare congenital vascular malformation which is usually localized to the lower extremity, unilaterally [2]. Even though, VVM has an immune profile analogous to the vascular proliferations; it exhibits histopathological features, clinical behavior and evolution pattern of vascular malformations [2,3]. VVM is present at birth or appears during early childhood, in the form unilateral, localized or grouped, erythematous patches which eventually transform into hyperkeratotic, confluent, dark

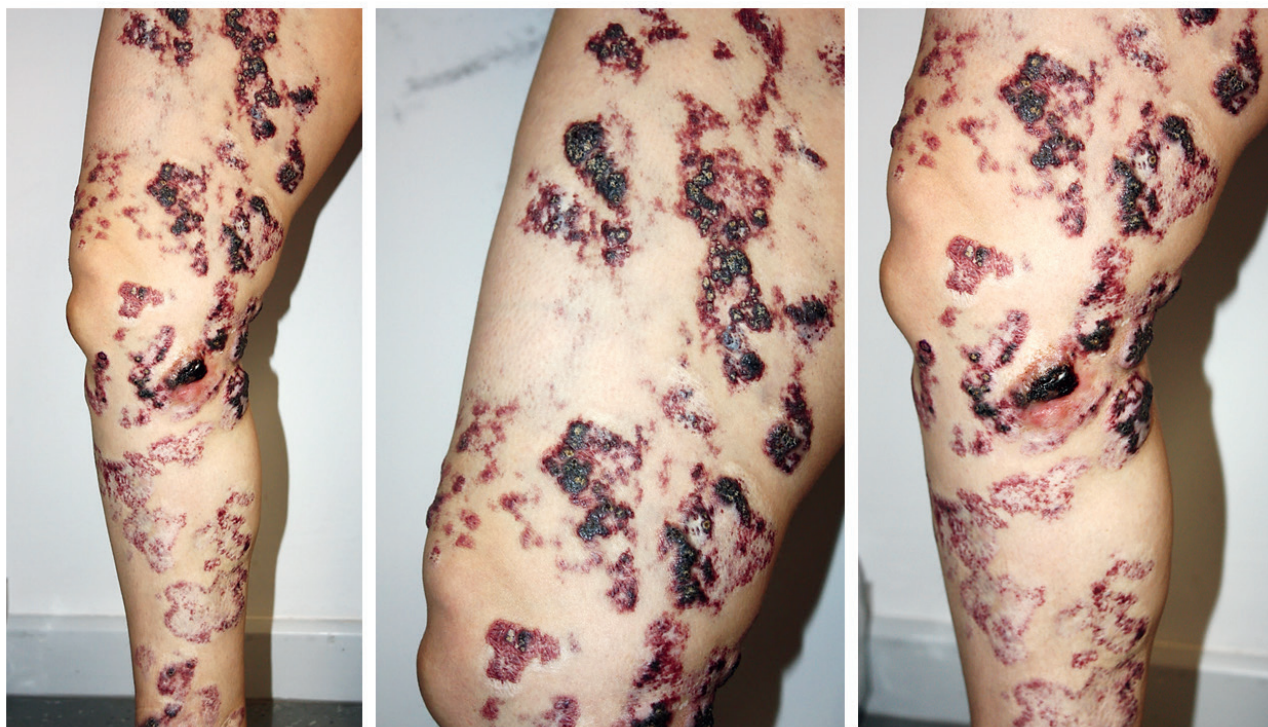

Figure 1. Multiple, violaceous to black, verrucous plaques and nodules of variables sizes accompanied by hyperkeratinization are present on the entire right thigh and leg. Some plaques on the right leg were excised and skin grafting was applied.

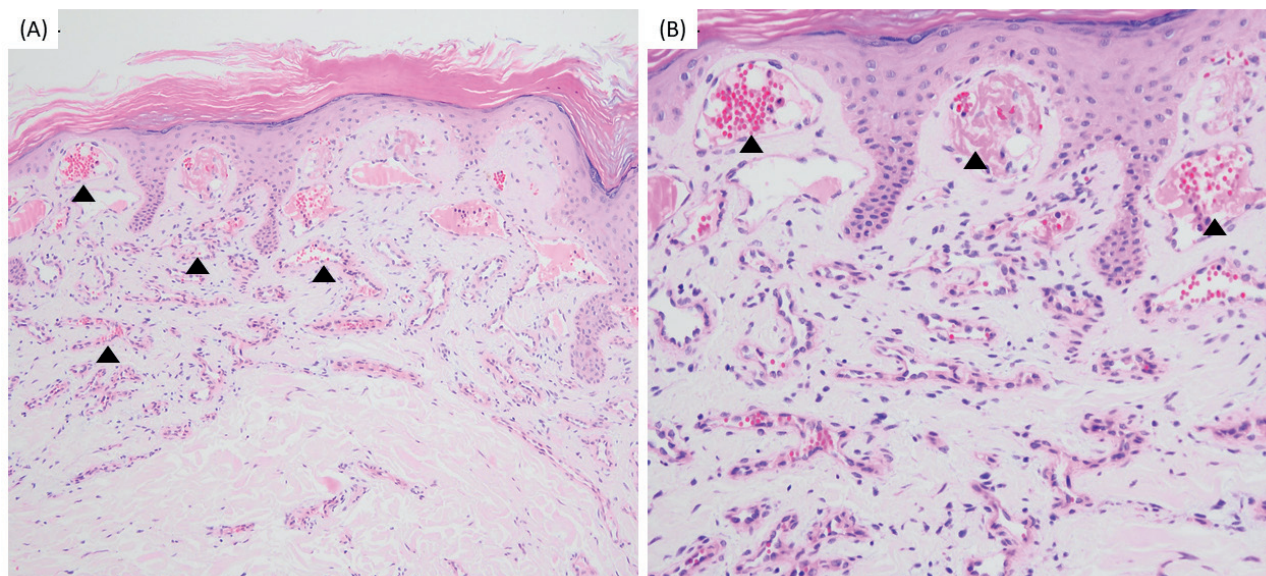


Figure 2. Hyperkeratosis with irregular acanthosis in the epidermis. Dilated vascular channels in between elongated rete ridges in the papillary dermis (arrowheads) (A), (H.E. x100). Dilated capillaries some filled with fibrinous thrombus (arrowheads) (B), (H.E. x200).

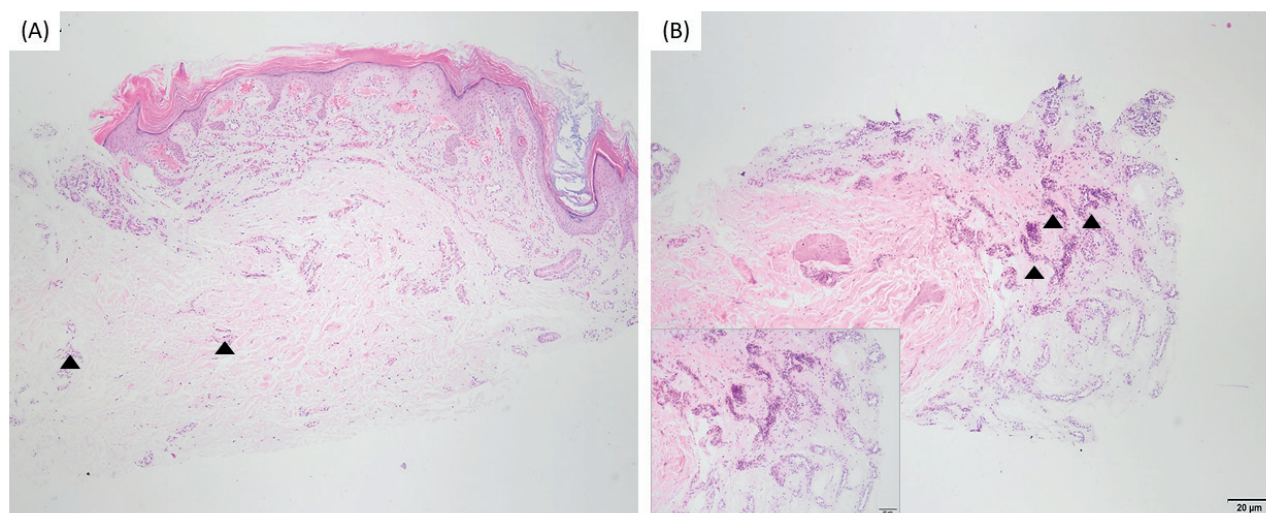


Figure 3. Although mid and deep dermis are seen spared, vascular proliferation is seen in subcutis (arrowheads) (A, B) (H.E. x40). Some malformed vessels in the subcutis (B,inset) (H.E. x200).

purple to black verrucous plaques and nodules on the lower extremities [2,3]. Unlike hemangiomas, VVM tends to progress and extend in proportion the child's growth and doesn't spontaneously regress [2,3]. ACN resembles VVM in terms of clinical presentation, behavior and course. ACN may range from a few centimeters to expansive plaques encovering a considerable part of the body most commonly involving the unilateral lower extremity even though neck involvement was also reported as a rare occurrence [2,4]. Since ACN and VVM can not be differentiated from each other based on clinical grounds, histopathological examination is the gold standard for the correct

diagnosis [2]. Angiokeratoma is characterized histopathologically by dilated, thin-walled vessels in the papillary dermis, whereas orthohyperkeratosis and cavernous vascular spaces encircled by flattened-malformed endothelial cells which may extend to the deeper dermis and subcutaneous tissue, are observed in VVM just like our case's histopathological examination findings revealed [2]. Surgical excision combined with skin grafting, CO₂ laser for residual or recurrent thick plaques and argon or pulse dye laser for thin, erythematous patches showed promising results in a study by Yang et al. [5]. In another study, it was shown that the thick- hyperkeratotic parts of VVM best

respond to CO₂ laser whereas the dual pulse dye laser-Nd:YAG laser is the treatment of choice for the deeper vascular components [6].

CONCLUSION

All in all, we want to emphasize that VVM is a rare vascular malformation that should be kept in mind as one of the differential diagnoses in patients presenting with unilateral, hyperkeratotic, verrucous vascular papules and plaques.

Author contribution

Study conception and design: EB, BYA, BY, and OG; data collection: EB, BY, and OG; draft manuscript

preparation: EB and BYA. All authors reviewed the results and approved the final version of the manuscript.

Ethical approval

Ethical committee approval was not needed for the present case report.

Funding

The authors declare that the study received no funding.

Conflict of interest

The authors declare that there is no conflict of interest.

REFERENCES

- [1] McCuaig CC. Update on classification and diagnosis of vascular malformations. *Curr Opin Pediatr.* 2017;29:448-454.
- [2] Oppermann K, Boff AL, Bonamigo RR. Verrucous hemangioma and histopathological differential diagnosis with angiokeratoma circumscriptum naeviforme. *An Bras Dermatol.* 2018;93:712-715.
- [3] Couto JA, Vivero MP, Kozakewich HP, et al. A somatic MAP3K3 mutation is associated with verrucous venous malformation. *Am J Hum Genet.* 2015; 96:480-486.
- [4] Sardana K, Koranne RV, Sharma RC, Mahajan S. Angiokeratoma circumscriptum naeviforme: rare presentation on the neck. *Australas J Dermatol.* 2001;42:294-295.
- [5] Yang CH, Ohara K. Successful surgical treatment of verrucous hemangioma: a combined approach. *Dermatol Surg.* 2002;28:913-919; discussion 920.
- [6] Segura Palacios JM, Boixeda P, Rocha J, et al. Laser treatment for verrucous hemangioma. *Lasers Med Sci.* 2012;27:681-684.